

# Perioperative Nursing of Balloon Occlusion Test and Embolization of Internal Carotid Artery for Locally Recurrent Nasopharyngeal Carcinoma

Wei Huang, Liantian Zhang, Litao Li, Yangkui Gu, Mengxuan Zuo\*

Department of Minimally Invasive Interventional, State Key Laboratory of Oncology in South China, Collaborative Innovation Center of Cancer Medicine, Sun Yat-Sen University Cancer Center, Guangzhou, P. R. China

## Email address:

zuomx@sysucc.org.cn (Mengxuan Zuo)

\*Corresponding author

## To cite this article:

Wei Huang, Liantian Zhang, Litao Li, Yangkui Gu, Mengxuan Zuo. Perioperative Nursing of Balloon Occlusion Test and Embolization of Internal Carotid Artery for Locally Recurrent Nasopharyngeal Carcinoma. *American Journal of Nursing Science*.

Vol. 11, No. 5, 2022, pp. 158-162. doi: 10.11648/j.ajns.20221105.16

**Received:** October 9, 2022; **Accepted:** November 2, 2022; **Published:** November 11, 2022

---

**Abstract:** *Background:* Surgical resection is the most effective treatment for the patients with locally recurrent nasopharyngeal carcinoma (NPC) in selected cases. Due to the complicated anatomical structure of nasopharynx, surgical resection may cause serious complications, including fatal bleeding. The subsequent implementation of internal carotid artery (ICA) embolization following a negative result of balloon occlusion test (BOT) can effectively reduce the risks of massive hemorrhage caused by the tumor or surgical management of the tumor. *Objective:* To explore the feasibility of perioperative nursing management for the patients with locally recurrent NPC underwent BOT and ICA embolization. *Materials and Methods:* This retrospective study investigated 81 locally recurrent NPC patients, who underwent BOT with or without following ICA embolization. Perioperative nursing management was performed for each case. In particular, close observations were conducted for the signs of brain function including consciousness, pupil size, vision, verbal ability, cognition, memory, limb movement, muscle strength, in comparison with the corresponding records before BOT. The positive or negative tested results of BOT, as well as the complications of BOT and ICA embolization were analyzed. The following nasopharyngeal surgeries was recorded. *Results:* A total of 82 BOTs were performed in 81 patients, including bilateral BOT in 1 case. The negative rate of BOT was 88.3% (76 of 82), which supported the option of ICA embolization procedure. After BOT, 75 patients underwent the following ICA embolization without neurological complications. Among them, 57 patients (76.0%) underwent subsequent salvage surgery to remove nasopharyngeal tumors without the occurrence of massive bleeding. The other 18 patients (24.0%) did not undergo salvage surgery due to tumor progression. *Conclusion:* Sequential implementation of BOT and ICA embolization reduced the risk of fatal bleeding during nasopharyngeal surgery, providing an opportunity for surgical treatment of locally recurrent NPC. Strict perioperative nursing management contributed to the successful treatment outcome.

**Keywords:** Nasopharyngeal Carcinoma, Balloon Occlusion Test, Embolization, Nursing

---

## 1. Introduction

China is an area with high prevalence of nasopharyngeal carcinoma (NPC), accounting for more than 40% of new cases in the world, among which South China, Hong Kong, and Macao have the highest incidence (up to 50 cases per 100,000 population) [1]. Radiation therapy is the most effective treatment for NPC. With the widespread use of

intensity-modulated radiation therapy (IMRT), the local control rates of NPC have been significantly improved, but there is still 10~36% of patients with local recurrence after initial treatment [2, 3]. Re-irradiation is usually reported with poor efficacy to treat recurrent lesions and may lead to serious complications [4]. Surgical resection radically removes the lesions insensitive to radiotherapy while avoiding re-irradiation. Thus, it is the most effective

treatment for patients with locally recurrent NPC. The nasopharynx is adjacent to many vital tissues and organs, especially the Internal Carotid Artery (ICA) in the parapharyngeal space, whose damage may lead to fatal bleeding. Balloon Occlusion Test (BOT) is widely performed to clinically assess the cerebral ischemic tolerance after occlusion of an ICA with a percutaneous and transvascular balloon [5]. The subsequent implementation of ICA embolization after BOT can effectively reduce the risks of massive hemorrhage caused by the possible occurrence of surgical injury to ICA. This article retrospectively analyzed 81 patients with local NPC recurrence after radiotherapy who underwent BOT and following ICA embolization in our hospital, and discussed the perioperative nursing measures.

## 2. Materials and Methods

### 2.1. Population Description

This analytic retrospective study investigated 81 patients with locally recurrent NPC in our hospital from September 2019 to November 2021. The results of preoperative nasopharyngoscopy, MR, or CT of all these patients showed local recurrence of nasopharyngeal carcinoma, soft tissue necrosis, or/and bone destruction. BOT was performed for each patient, followed by scheduled subsequent surgical resection of nasopharyngeal tumor. There were 60 males and 21 females, aged 19-75 years ( $50.4 \pm 10.8$  years). Forty-eight cases (59.26%) had soft tissue necrosis in the nasopharynx, and 59 cases (72.84%) had bone destruction of the skull base.

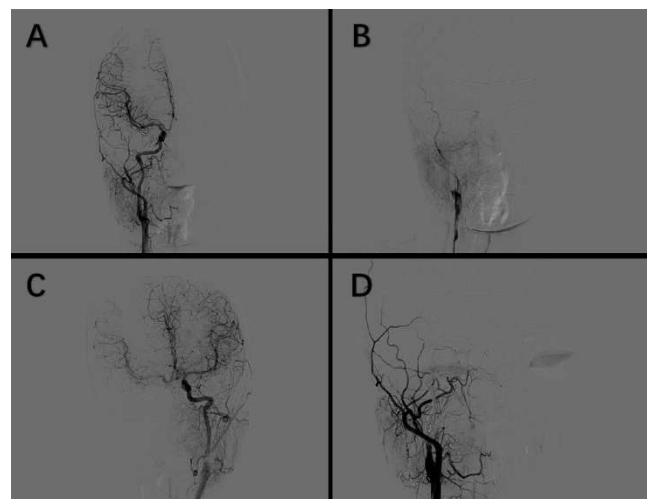
### 2.2. Methods

**Preoperative Examination:** laboratory tests including blood, urine and stool tests, liver and kidney function, hemostasis/coagulation test, blood type, and other examinations; electrocardiogram; nasopharyngeal endoscopy, head CT, MRA, and other imaging examinations.

**Indications and Contraindications** Indication: locally recurrent NPC after radiotherapy with scheduled subsequent surgical resection of NPC. Contraindications include the history of iodine allergy, severe cardiac/hepatic/renal dysfunction, bleeding/coagulation dysfunction or bleeding disorders; severe/uncontrolled hypertension; severe cerebral arteriosclerosis; severe variations of the cerebrovascular arterial ring (Circle of Willis).

**Methods of BOT and ICA Embolization** Prior to BOT: the carotid compression test (Matas test) was routinely performed for those who could tolerate the Queckenstedt test well, and BOT was not implemented for those with positive results of the Queckenstedt test. The conventional Seldinger method was used to puncture the femoral artery. Bilateral carotid and vertebrobasilar angiography were performed to understand the intracranial vascular structure, observe the integrity of the Willis circle, and find whether there was staged stenosis, secondary arterial injury, or tumor vasculature of nutrition supply. For systemic heparinization, the first dose of heparin administration was 0.6-0.7 mg/kg,

and an additional dose was added based on the duration of the operation. The 6F (French) catheter was inserted into the corresponding artery, and an appropriate balloon was selected and placed by the guide wire to insert the balloon catheter (diameter 5.0mm, balloon length 20mm) into the internal carotid artery, and the position was confirmed according to the markings at both ends located in the C1 segment (Bouthillier section). After the balloon catheter reached the specific position, the contrast agent was injected into the balloon using the filling pressure pump system to fill the balloon, and the complete arterial blockage was confirmed by angiography. The blocking time is usually 30 minutes, and some patients need more blocking time depending on clinical needs. The National Institutes of Health Stroke Scale (NIHSS) was used as the criterion for evaluating BOT [6]. If the patient develops cerebral ischemia (obvious discomforts or neurological dysfunction, etc.) after the ICA is blocked, the test result is positive, and the BOT is terminated by emptying the balloon immediately. If the patient has no certain discomfort, no neurological dysfunction or cognitive decline, the patient can tolerate BOT well, and the test result is negative. For patients who can tolerate BOT, the contrast agent in the balloon was withdrawn, and the microcatheter was directed to the distal end of the carotid artery along the catheter, followed by gradually retreats and releasing of several electrolytic coils to embolize the region from the upper part of the cervical segment of the internal carotid artery to the cavernous sinus segment. Internal carotid angiography was performed again after embolization to check the integrity of the embolization (Figure 1).



**Figure 1.** A: right carotid angiography was performed. B: balloon (diameter 5.0mm, balloon length 20mm) was placed by the guide wire into the internal carotid artery, and the contrast agent was injected into the balloon, and the complete arterial blockage was confirmed by angiography. C: left carotid angiography was performed. D: several electrolytic coils were released to embolize the right carotid artery.

**Evaluation Indicators of BOT Tolerance:** NIHSS is composed of 15 items including language, cognition, visual field, movements, sensation, and reflex. NIHSS achieves a high level of validity and reliability unaffected by different

assessors, and it is an assessment tool widely used for clinically evaluating acute stroke. BOT-negative: score of each NIHSS item is 0 point, with no ischemic symptoms; BOT-positive: NIHSS total score  $\geq 1$  point, with any clinical symptoms [6].

**Preoperative Care** (1) Pre-operative discussion: The interventional operating room nurses participated in the pre-operative discussion with doctors, familiarized themselves with the patient's health status, clarified the precautions during the operation and evaluation methods, and understood the operation procedures and cooperation; communicated with the patient and family to explain the disease and operation procedures, and let them sign the relevant informed consent document. (2) Equipment preparation: digital subtraction angiography machine, high-pressure injector, ECG monitor, micro syringe pump, oxygen system and phlegm suction machine, infusion pump, cardiac defibrillator, self-inflating bag, ambulance. (3) Medication preparation: contrast agent (iomeprol, ioversol, etc.), lidocaine, heparin sodium, nitroglycerin injection solution, vasopressin, Ringer's solution, 0.9% sodium chloride, and first aid medication (if necessary). (4) Preparation of surgical instruments. (5) Guidance on intraoperative cooperation and health education: explained the operation principle, necessity, operation procedures, complication prevention and precautions before and after operation to the patient before surgery, offered a detailed account of the key points of intraoperative cooperation and the evaluation content of carotid compression test, conduct the toileting training for the bedridden patients. (6) Preoperative preparation: Local anesthesia was used; patients were required to fast for 2 hours before the operation; assisted the patient to wear the surgical gowns, removed any jewelry and dentures, and removed the nail polish; Skin preparation: from below the navel to 1/3 of the upper thigh; indwelling urinary catheter and indwelling bilateral upper extremity venous catheter were employed to establish 2 venous channels; patient identification, name of surgery, surgical site, history of iodine allergy, and past medical history were checked according to the routine operation; (7) Preoperative blood pressure measurement: monitored the patient's preoperative blood pressure as the basal blood pressure level before BOT, and injected antihypertensive drugs by the micro syringe pump to control blood pressure. (8) Psychological care: Anxiety and fear during the preoperative period are common problems for patients. Nurses should patiently explain about surgery, comfort patients, and guide them to conduct psychological relaxation training when necessary to relieve preoperative anxiety and fear.

**Intraoperative Care** (1) Pillow-free horizontal position was used during the operation, and patients' needs for comfort and warmth were considered. (2) During the BOT procedure, ECG, oxygen inhalation, the patient's condition, and vital signs were closely monitored. (3) Under systemic heparinization, the BOT test was performed for 30 minutes after the balloon was inflated, and the patient was asked to keep verbally communicating with health care team members

and move the contralateral limb of the embolized blood vessel every 5 minutes. (4) Intraoperative evaluation: NIHSS was used to evaluate the patient's consciousness, sensation, reaction, language, extremity movements, muscle strength, and the ability of mathematical and logical calculations. (5) Kept the patency of intravenous infusion and antithrombotic agents were given by pressurized perfusion to flush the channel. (6) Recorded the patient situation in detail at two key time points: the first time point was the implementation of systemic heparinization when the catheter was inserted into the vertebral artery and 5000U low-molecular-weight heparins were firstly administered by intravenous bolus injection. 3000U heparins were administered again after 1 hour; Another time point was when the artery was occluded after the balloon was inflated, and contralateral internal carotid arteriography was performed every 10 minutes after occlusion to assess the compensation of the blood circulation in the posterior communicating artery.

**Postoperative care** (1) Care of the puncture site: The catheter and sheath were removed in the femoral artery. Sutured and compressed the puncture site with an elastic bandage. Checked the compression strength of the elastic bandage on puncture sites of the bilateral femoral artery, and focused on observing whether there was a hematoma or active bleeding at the puncture points of the bilateral groin. Applied sandbags to compress the wounds for 6 hours. Instructed the patient to immobilize both lower extremities for 12 hours, and observed the skin color, temperature, sensory perception, and the dorsal arterial pulsation of the punctured limb every 2 hours, which could prevent the blood flow from being blocked due to an overly tight bandage or even the formation of thrombus. If there is no bleeding at the puncture site, the dressings over it can be removed after 24 hours. (2) Monitored changes in blood pressure: As antihypertensive drugs may be used during surgery, it is necessary to closely monitor the recovery of blood pressure after surgery to stabilize blood pressure. The high variation of blood pressure can easily cause symptoms such as bleeding and dizziness; those with high blood pressure should maintain blood pressure at a slightly higher level before its onset to ensure cerebral perfusion and prevent the growth of cerebral infarction. However, if the blood pressure is  $> 220/120\text{mmHg}$ , the use of antihypertensive drugs is generally not recommended. (3) Instructed the patient to turn head slowly, keep emotionally stable, and stay in bed for more than 6 hours. (4) Monitored vital signs and blood sugar levels: routine electrocardiographic monitoring, close monitoring of the changes of vital signs. Oxygen was delivered at a middle flow rate, and adjusted the flow rates according to the level of blood oxygen saturation; paid attention to blood sugar conditions to avoid hypotensive shock induced by hypoglycemia. (5) Monitored the related signs of the patient's brain function: evaluated the patient's consciousness, pupils, vision, language, cognition, memory, limb movements, muscle strength, gait, etc., and compared them with the corresponding recordings during the preoperative period. (6) Caution of the warning signs of

cerebral infarction: timely identified the clinical symptoms of cerebral infarction caused by insufficient cerebral blood supply after surgery, such as dizziness, headache, limited mouth opening, facial paralysis, facial hypoesthesia/numbness, vomiting, dysarthria, aphasia, unilateral vision blurred vision, hemianopia or total blindness, abnormal sensory and motor function of limbs, decreased muscle strength, epilepsy, confusion, and other neurological symptoms; if the patient develops the abovementioned symptoms of cerebral infarction, the doctor should be notified in time and give the corresponding treatments for patients with cerebral infarction, such as volume expansion, anticoagulation, thrombolysis, etc., followed by close observation and care. (7) Ankle pump exercises: guided patients to perform ankle pump exercises during the immobilization of both lower limbs to prevent deep vein thrombosis, repeated every 1 hour, minutes/each time. (8) Quality nursing care: Assisted the bedridden patients to turn every 2 hours, observed the pressed conditions of the skin, and provided the bed Wedge pillows to improve comfort; focused more on basic nursing care and assisted the patient with toileting on the bed.

Discharge guidance (1) Patients need to take enough rest, get adequate sleep, be emotionally stable, avoid excessive excitement and nervousness, and take antihypertensive drugs to control blood pressure as prescribed by the doctor. (2) Improve nutrition, have a bland diet that has high protein and high calories, choose easy-to-digest foods, avoid spicy and irritating foods, quit smoking and alcohol; consume regular meals to avoid hypoglycemia-induced hypotensive shock, especially diabetic patients should be alert to the occurrence of nocturnal hypoglycemia. (3) Keep a normal bowel movement. Patients with constipation should take stool softeners, and increase the consumption of vegetables, fruits, and whole grains rich in fiber to prevent cerebrovascular symptoms caused by increased abdominal pressure from constipation. (4) Inform the patient and family that the common complications 1 week after the operation are cerebral vasospasm or brain ischemia. Keep track of changes in the patient's consciousness, pupils, language, limb muscle strength, etc., and if there are any abnormalities, let the patient seek medical care immediately.

### 3. Results

#### 3.1. BOT and Its Complications

A total of 82 BOTs were performed in 81 patients, including 1 patient who underwent bilateral ICA BOT. The negative rate of BOT was 88.3% (76 of 82), 1 case did not perform BOT due to carotid artery occlusion, 5 cases experienced early termination of BOT because of obvious neurological symptoms (the positive rate was 11.7%) including consciousness disturbance, or/and movement disorders of the lateral limbs, abnormal muscle strength. There were no BOT-related technical complications in the 82 BOTs (the intraoperative complication rate was 0%), such as

cerebral embolism and balloon rupture.

#### 3.2. ICA Embolization and Surgical Treatment of NPC

After BOT, 75 patients underwent ICA embolization, and all patients experienced no neurological complications. 2 cases performed the simultaneous embolization of the ipsilateral maxillary artery to treat nasopharyngeal tumor-associated hemorrhage. 57 patients (76.0%) underwent subsequent salvage surgery to remove nasopharyngeal tumors, and no ICA hemorrhage occurred. 18 patients (24.0%) did not undergo salvage surgery due to tumor progression.

### 4. Discussion

Locally recurrent NPC has always been a challenging problem in clinical treatment. Surgical treatment can effectively remove the lesions and prolong the survival period of patients [7]. However, it has certain difficulties and risks [8-10]. The main reason is that the nasopharynx is deeply located in the center of the skull and the full exposure of the nasopharynx cavity requires the face opening by the nasal external route. Furthermore, it is difficult to achieve radical resection due to the large area of lesions. The nasopharynx is adjacent to some vital structures, especially the ICA in the parapharyngeal space, and accidental injury to it during surgery can be life-threatening. Therefore, most patients with local recurrence are treated by re-irradiation. However, locally recurrent NPC after radiotherapy is usually insensitive to secondary radiotherapy due to poor efficacy and severe complications [4]. Salvage surgery directly removes radiotherapy-insensitive lesions, avoids damage from re-irradiation, and has fewer postoperative complications. The 5-year overall survival (OS) rate after salvage surgery was 58%, which was higher than patients treated with second-course radiotherapy (26~45%) [11, 12]. The application of new technologies such as ICA embolization and intracranial vascular bypass has expanded the indications of salvage surgery [13]. For patients with tumors or necrotic lesions close to the ICA, preoperative angiography should be performed to assess the risks of hemorrhage and hemiplegia caused by intraoperative accidental injury to the ICA. Some studies reported that preventive embolization should be employed for patients before surgery with negative BOT and elevated risks of intraoperative ICA bleeding [14].

BOT is a medical technology extensively applied to assess the tolerance of brain tissues, changes in intracranial hemodynamics after arterial occlusion, and whether patients can tolerate arterial occlusion therapy well, and to determine the maximum time for temporary arterial occlusion, which provides clinical evidence for choosing the appropriate treatment [5, 15]. In our investigation, 5 cases (5 of 82, 6%) developed neurological symptoms during the occlusion, which were relieved after the artery was unblocked. 76 cases (75 cases) underwent complete BOT, 75 cases performed subsequent ICA embolization and 57 cases experienced nasopharyngeal tumor resection, which effectively prevented serious complications caused

by accidental ICA injury during surgery. In the most comprehensive study of BOT research to date, Mathis et al. reported only 16 of 500 patients (3.2%) who underwent ICA BOT experienced complications [16].

Balloon occlusion test and embolization of the internal carotid artery are complicated surgeries that perform vascular interventions. Quality perioperative care and cooperation are required for a favorable prognosis. The emphasis of preoperative nursing is completing the clinical check and preparation of surgical equipment, instruments, medications, and patients. The key point of intraoperative nursing is to guide patients to complete the carotid compression test and keep track of all clinical signs. The focus of postoperative nursing is to observe and prevent postsurgical complications. Our understandings of nursing are as follows: (1) Carotid compression test is routinely performed for those who can tolerate the Queckenstedt test well, and BOT should not be performed for those who have positive results in the Queckenstedt test. (2) Check the integrity of the balloon catheter before surgery. Overly inflated balloon during surgery, stretching after inflation and other operation mistakes may damage the vascular intima, resulting in vascular damage such as pseudoaneurysm or arterial dissection. (3) Emphasis on the competence of systematic heparinization. If heparinization is incomplete, microthrombi will appear around the balloon during BOT, and these microthrombi may fall off causing embolic complications. It is necessary to achieve complete heparinization before surgery and administer an additional dose if needed during surgery. The patient's vital signs are closely observed after systematic heparinization. (4) For patients who took antihypertensive drugs during surgery, blood pressure recovery should be closely monitored after surgery, as fluctuations of blood pressure can cause bleeding, dizziness, and other symptoms. (5) Patients with advanced locally recurrent nasopharyngeal carcinoma after radiotherapy are vulnerable to experiencing nasopharyngeal hemorrhage. Therefore, it is needed to observe the changes in the patient's health status and prepare the rescue strategies for nasopharyngeal hemorrhage during the perioperative period.

## 5. Conclusion

Sequential implementation of BOT and ICA embolization reduced the risk of fatal bleeding during nasopharyngeal surgery, providing an opportunity for surgical treatment of locally recurrent NPC. Strict perioperative nursing management contributed to the successful treatment outcome.

## Abbreviations

NPC, nasopharyngeal carcinoma; ICA, internal carotid artery; BOT, balloon occlusion test; IMRT, intensity-modulated radiation therapy; NIHSS, The National Institutes of Health Stroke Scale; OS, overall survival.

## References

- [1] Fu, Z. T., et al., *[Incidence and mortality of nasopharyngeal carcinoma in China, 2014]*. Zhonghua Zhong Liu Za Zhi, 2018. 40 (8): p. 566-571.
- [2] Lee, V., et al., *Palliative systemic therapy for recurrent or metastatic nasopharyngeal carcinoma - How far have we achieved?* Crit Rev Oncol Hematol, 2017. 114: p. 13-23.
- [3] Kong, F., et al., *Long-term survival and late complications of intensity-modulated radiotherapy for recurrent nasopharyngeal carcinoma*. BMC Cancer, 2018. 18 (1): p. 1139.
- [4] Lee, A. W. M., et al., *Management of locally recurrent nasopharyngeal carcinoma*. Cancer Treat Rev, 2019. 79: p. 101890.
- [5] American Society of, I. and N. Therapeutic, *Carotid artery balloon test occlusion*. AJNR Am J Neuroradiol, 2001. 22 (8 Suppl): p. S8-9.
- [6] Odderson, I. R., *The National Institutes of Health Stroke Scale and its importance in acute stroke management*. Phys Med Rehabil Clin N Am, 1999. 10 (4): p. 787-800, vii.
- [7] Liu, J., et al., *Salvage endoscopic nasopharyngectomy for local recurrent or residual nasopharyngeal carcinoma: a 10-year experience*. Int J Clin Oncol, 2017. 22 (5): p. 834-842.
- [8] Bossi, P., et al., *Nasopharyngeal carcinoma: ESMO-EURACAN Clinical Practice Guidelines for diagnosis, treatment and follow-up (dagger)*. Ann Oncol, 2021. 32 (4): p. 452-465.
- [9] Chen, Y. P., et al., *Chemotherapy in Combination With Radiotherapy for Definitive-Intent Treatment of Stage II-IVA Nasopharyngeal Carcinoma: CSCO and ASCO Guideline*. J Clin Oncol, 2021. 39 (7): p. 840-859.
- [10] Wu, L. R., et al., *Validation of the 8th edition of AJCC/UICC staging system for nasopharyngeal carcinoma: Results from a non-endemic cohort with 10-year follow-up*. Oral Oncol, 2019. 98: p. 141-146.
- [11] Wei, W. I. and D. L. Kwong, *Current management strategy of nasopharyngeal carcinoma*. Clin Exp Otorhinolaryngol, 2010. 3 (1): p. 1-12.
- [12] Han, F., et al., *Long-term outcomes and prognostic factors of re-irradiation for locally recurrent nasopharyngeal carcinoma using intensity-modulated radiotherapy*. Clin Oncol (R Coll Radiol), 2012. 24 (8): p. 569-76.
- [13] Yang, R., et al., *Balloon Test Occlusion of Internal Carotid Artery in Recurrent Nasopharyngeal Carcinoma Before Endoscopic Nasopharyngectomy: A Single Center Experience*. Front Oncol, 2021. 11: p. 674889.
- [14] Zou, X., et al., *A curative-intent endoscopic surgery for postradiation nasopharyngeal necrosis in patients with nasopharyngeal carcinoma*. Cancer Commun (Lond), 2018. 38 (1): p. 74.
- [15] Sorteberg, A., et al., *Angiographic balloon test occlusion and therapeutic sacrifice of major arteries to the brain*. Neurosurgery, 2008. 63 (4): p. 651-60; discussion 660-1.
- [16] Mathis, J. M., et al., *Temporary balloon test occlusion of the internal carotid artery: experience in 500 cases*. AJNR Am J Neuroradiol, 1995. 16 (4): p. 749-54.